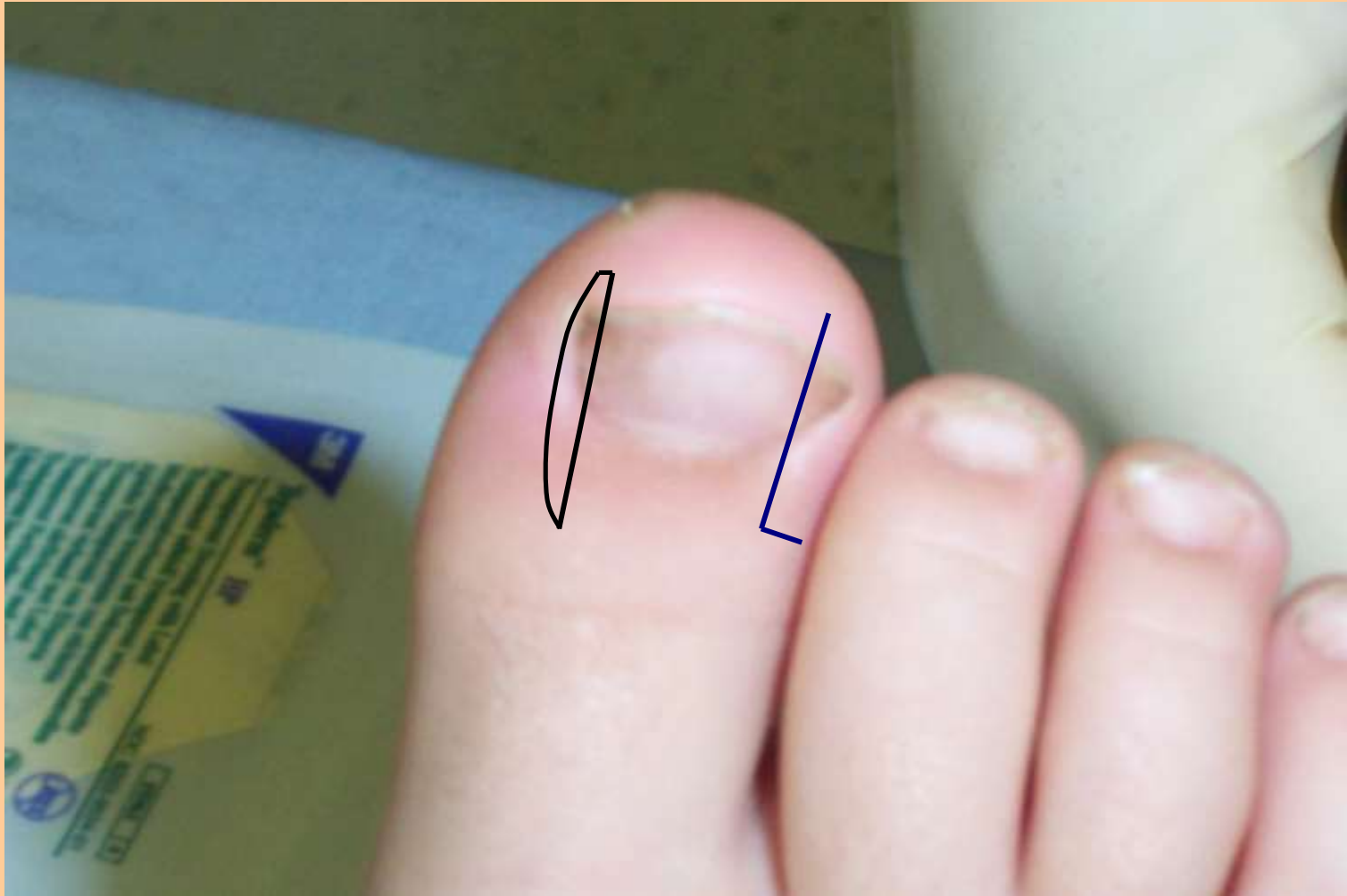

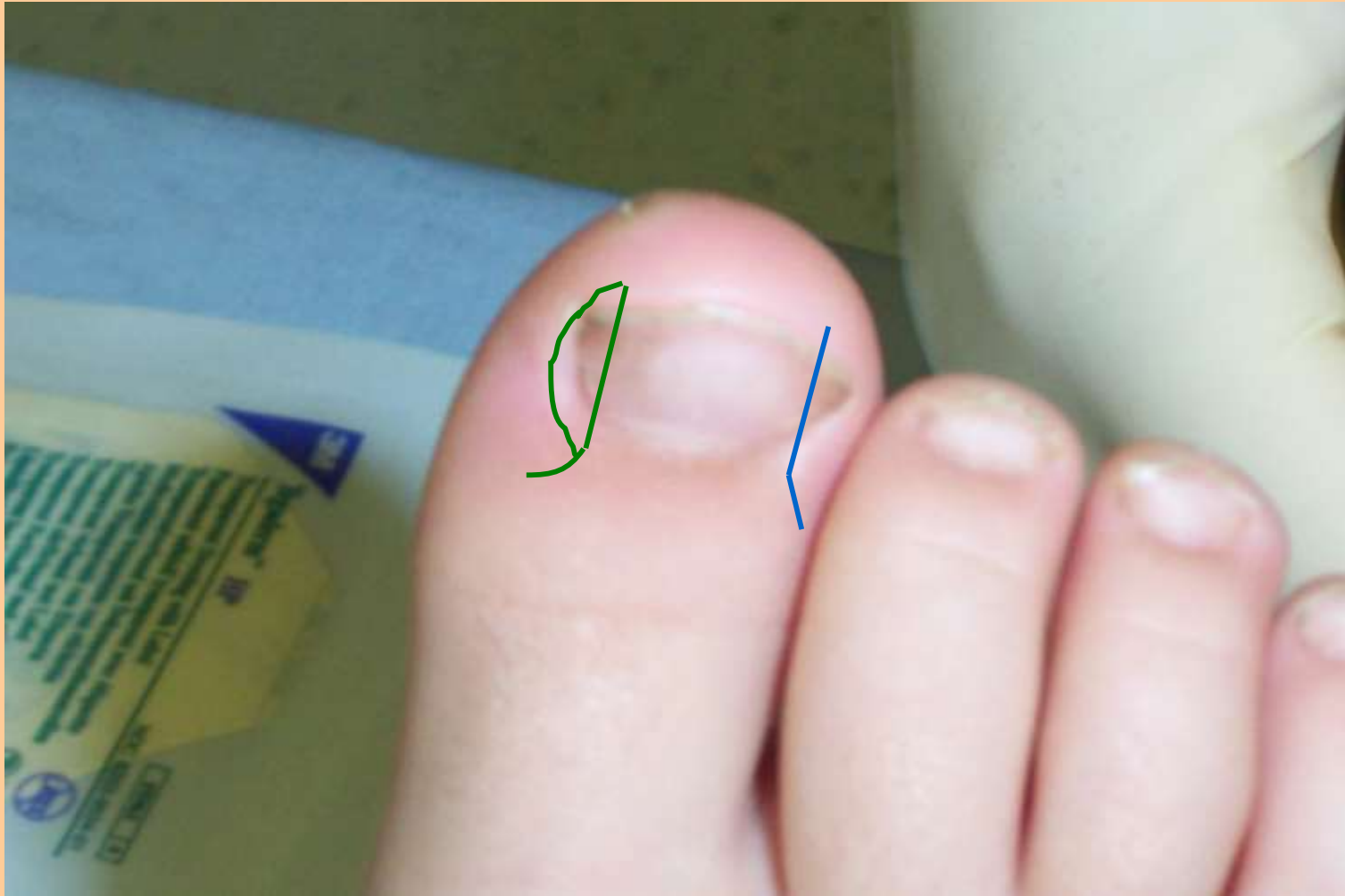Modified Winograd – partial nail excision



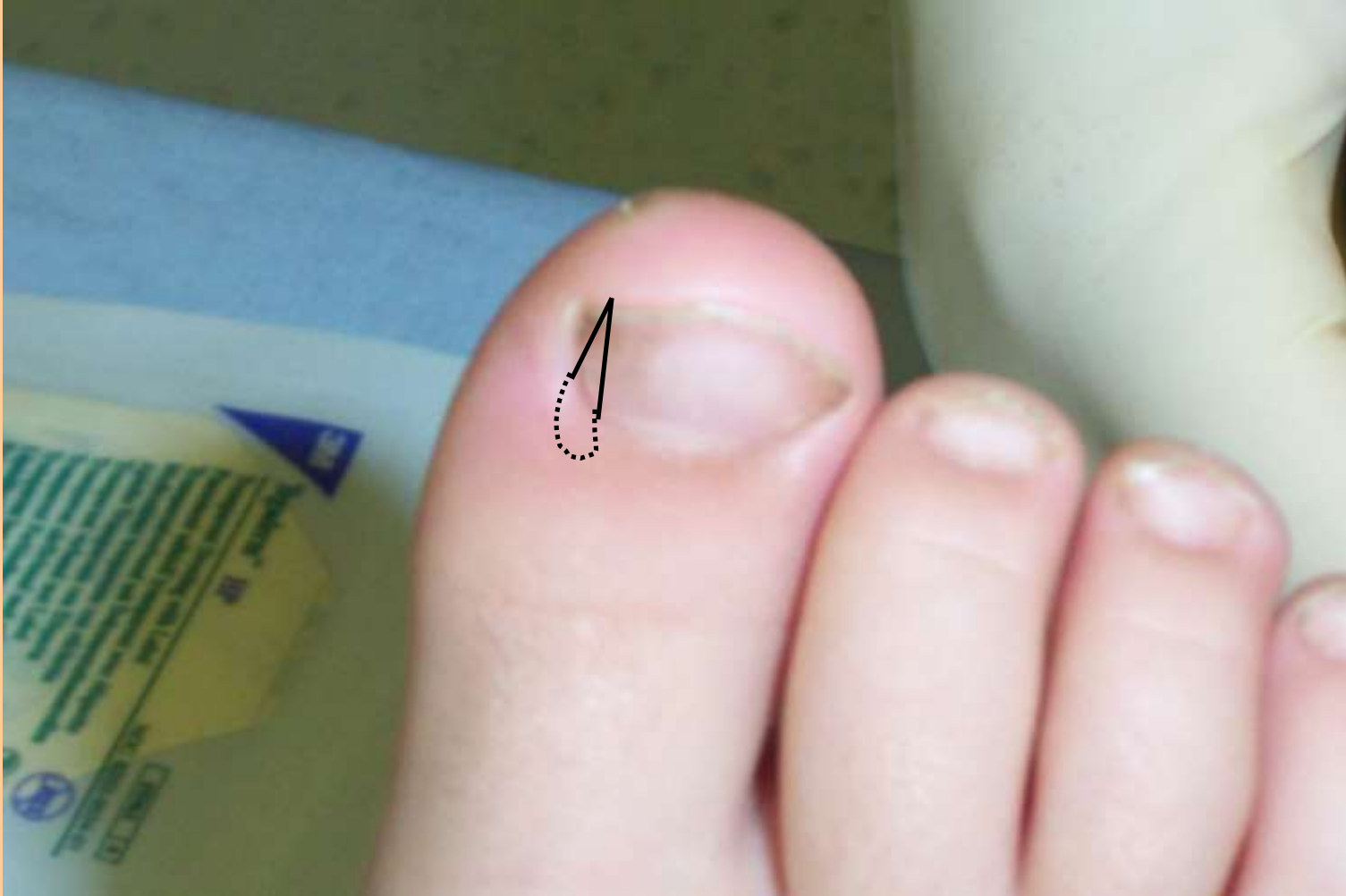Frost

Steindler

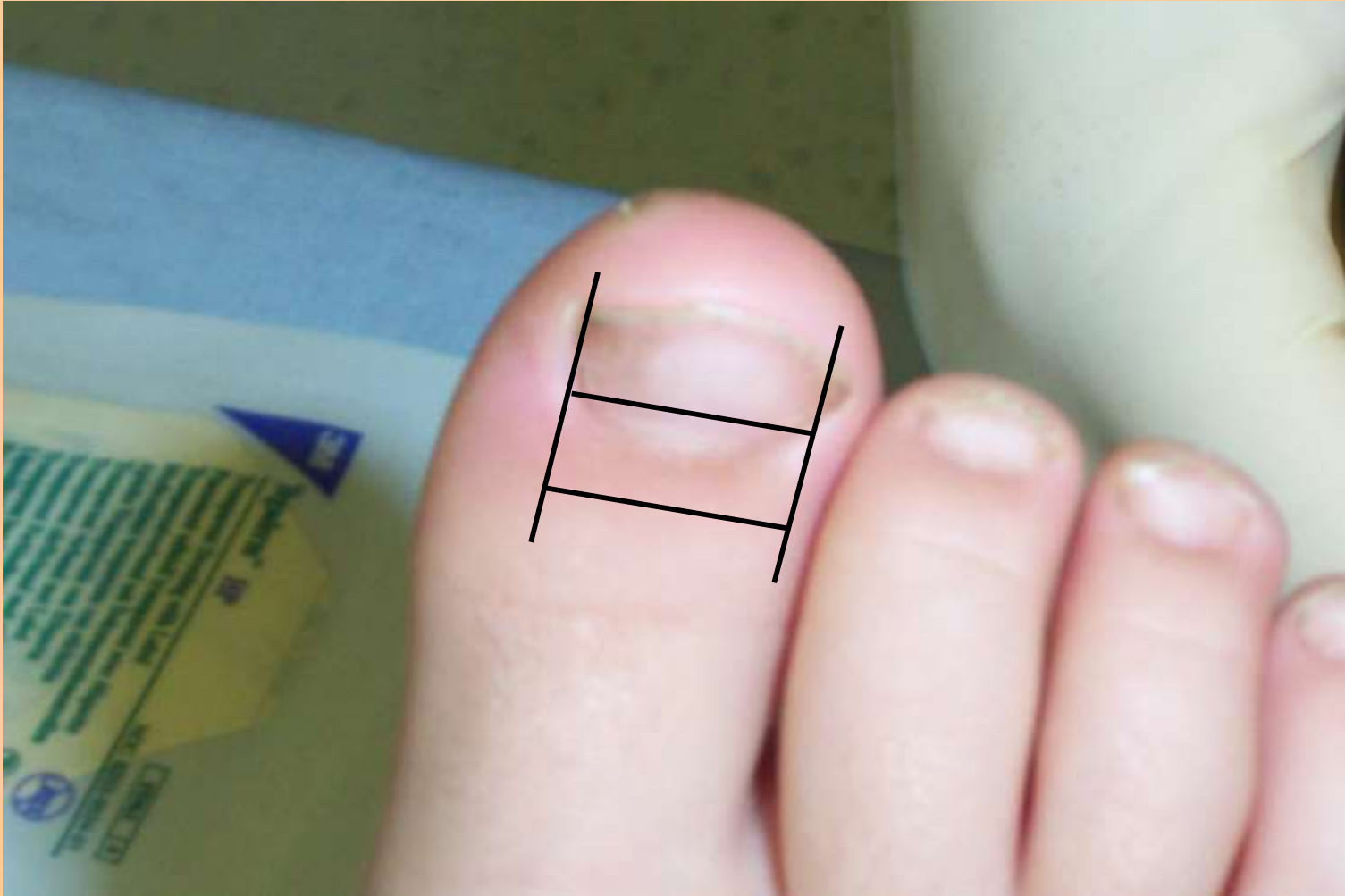
Modified Steindler – partial nail excision



Suppan – partial nail excision

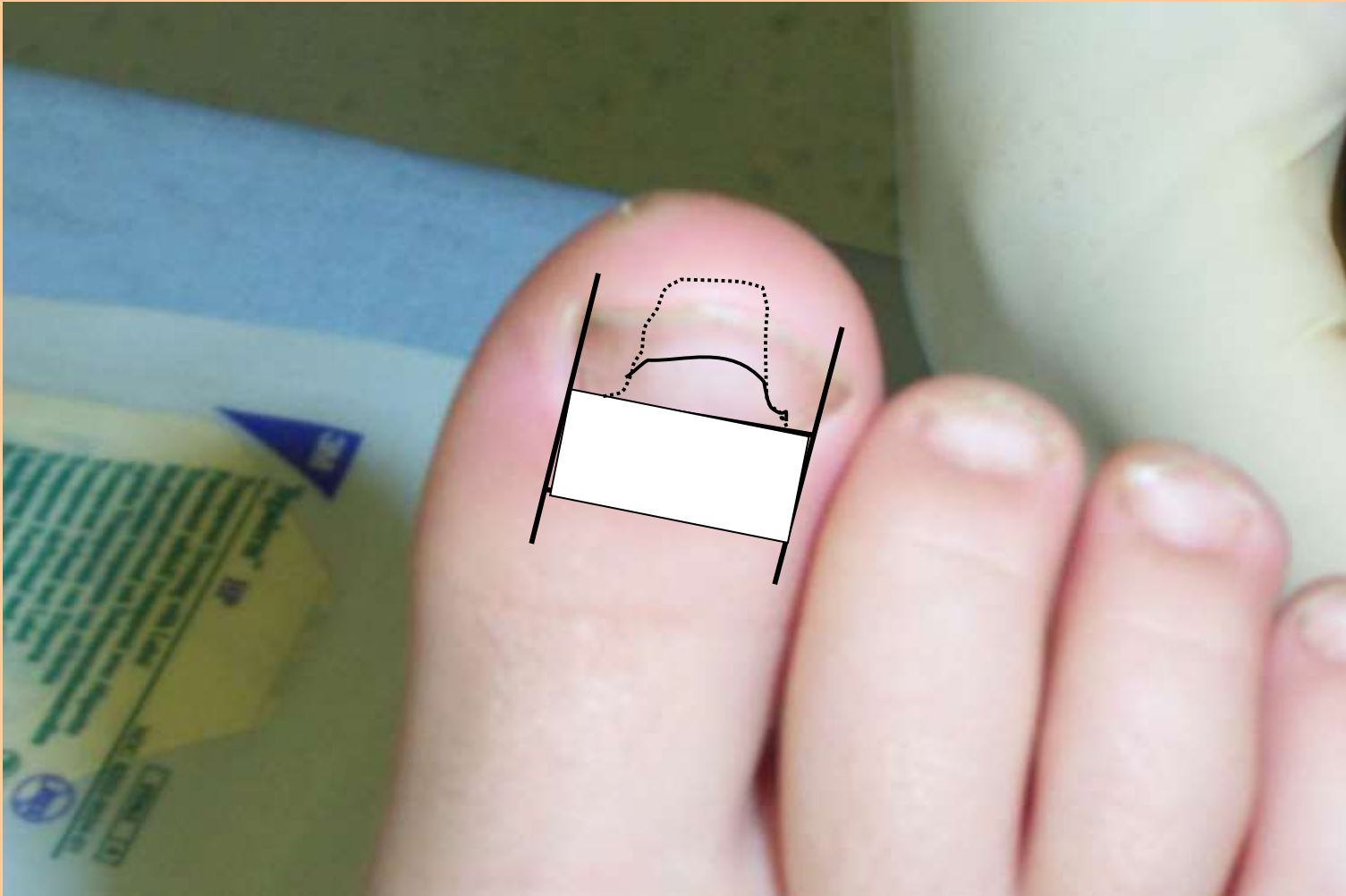


Zadick – total nail excision



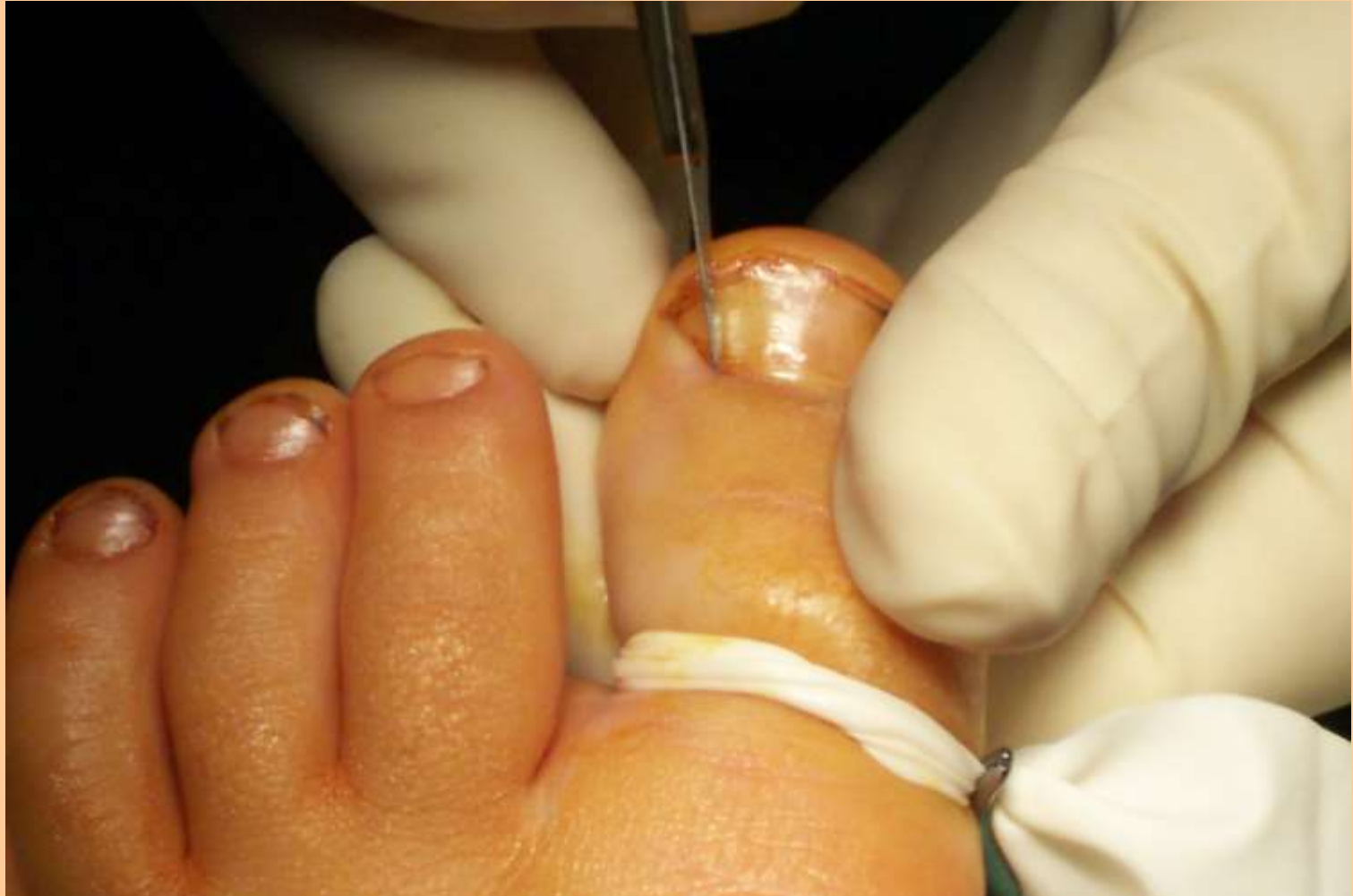1. Avulsion of nail plate

Zadick

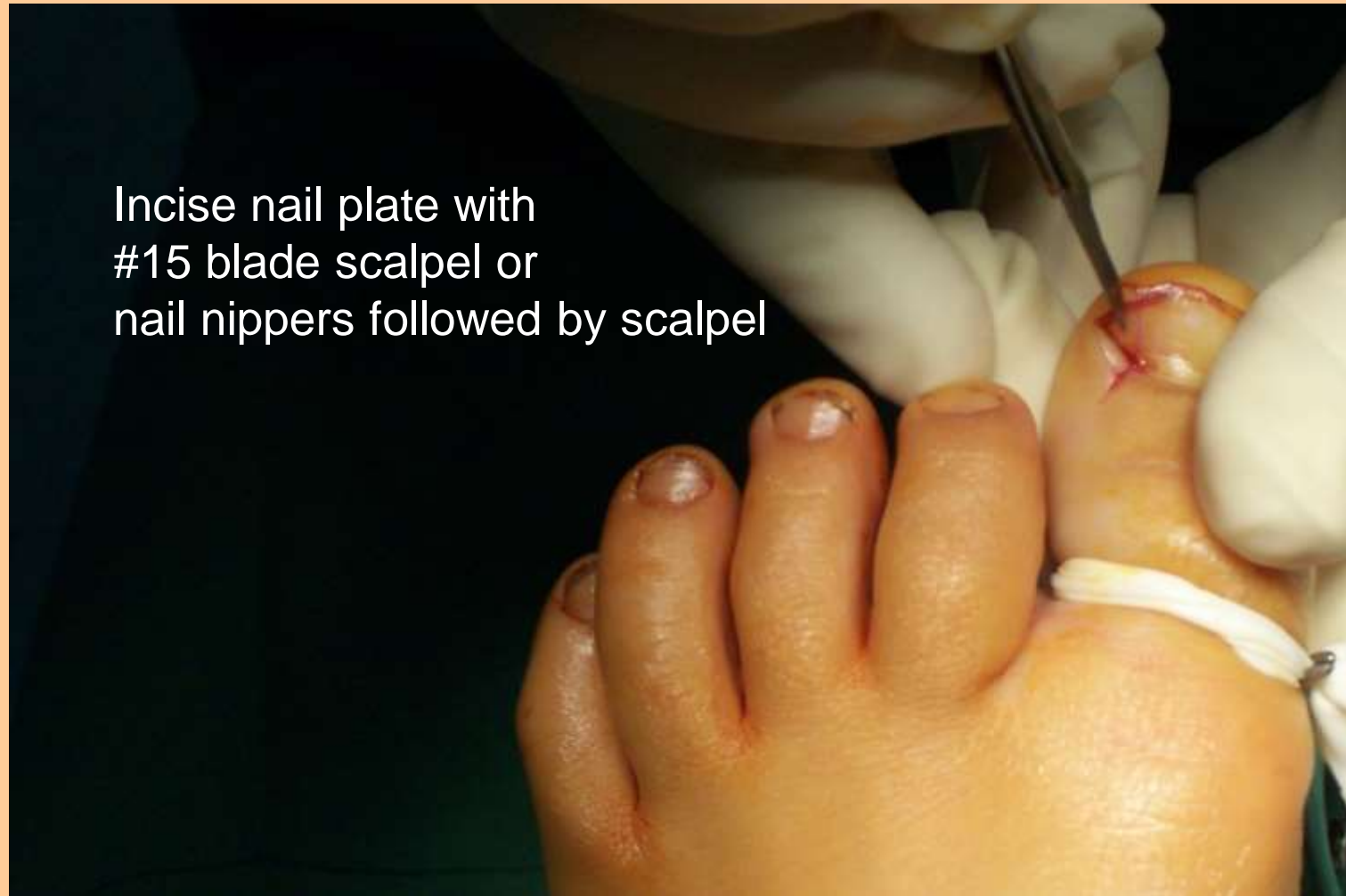

2. Excision nail bed/matrix → 3. Removal tuft distal phalanx

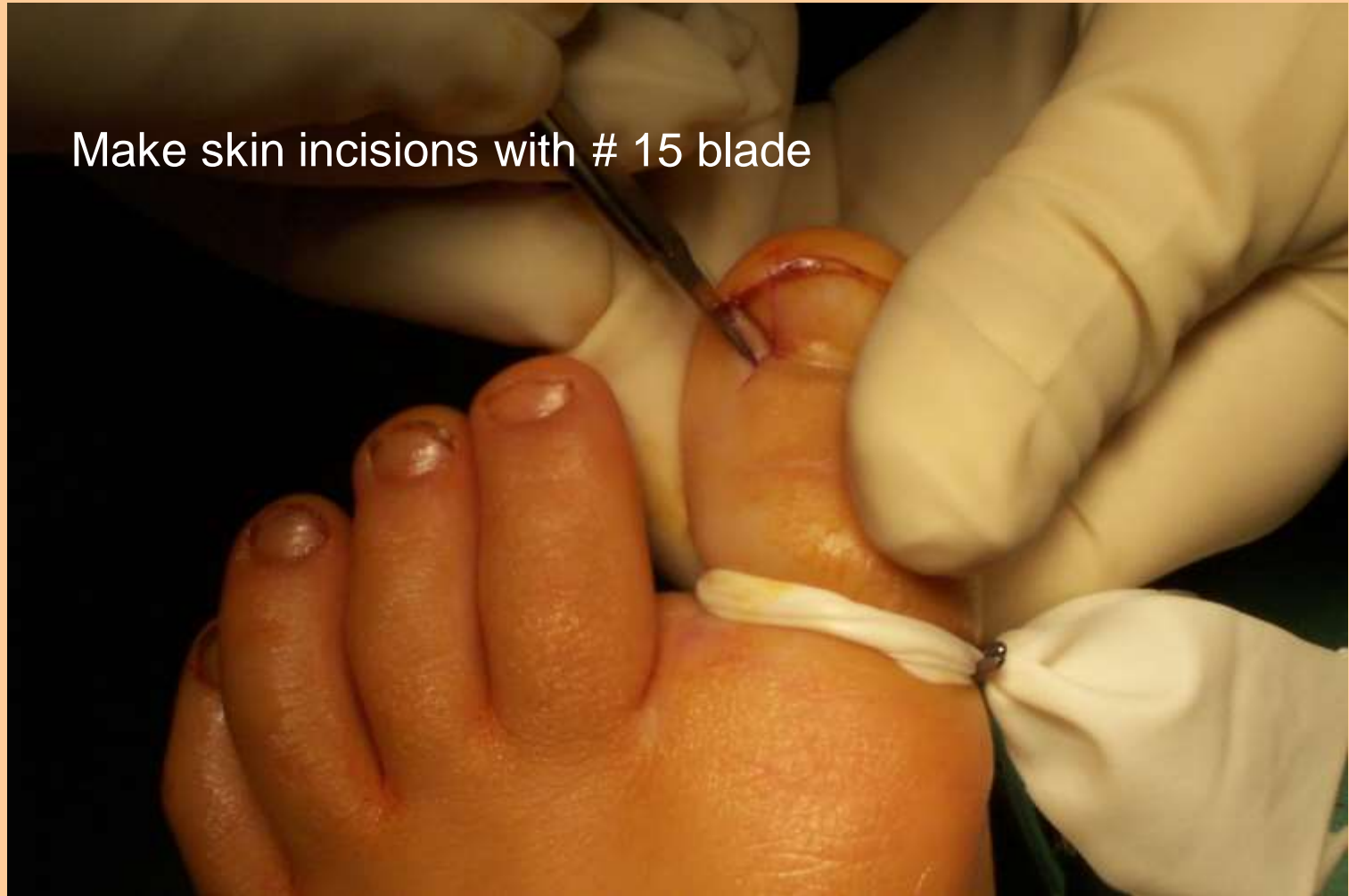Modified Winograd/Steindler

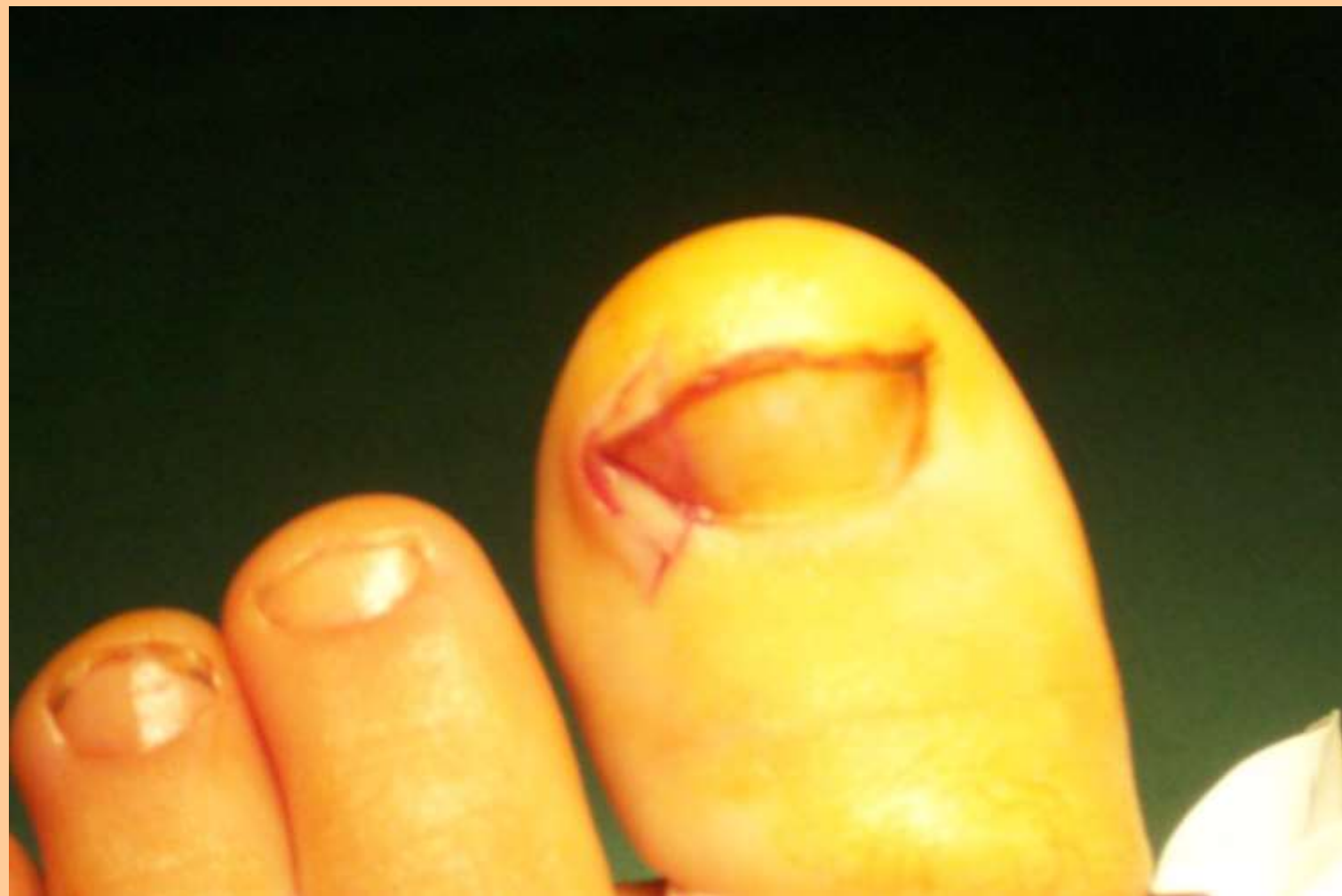

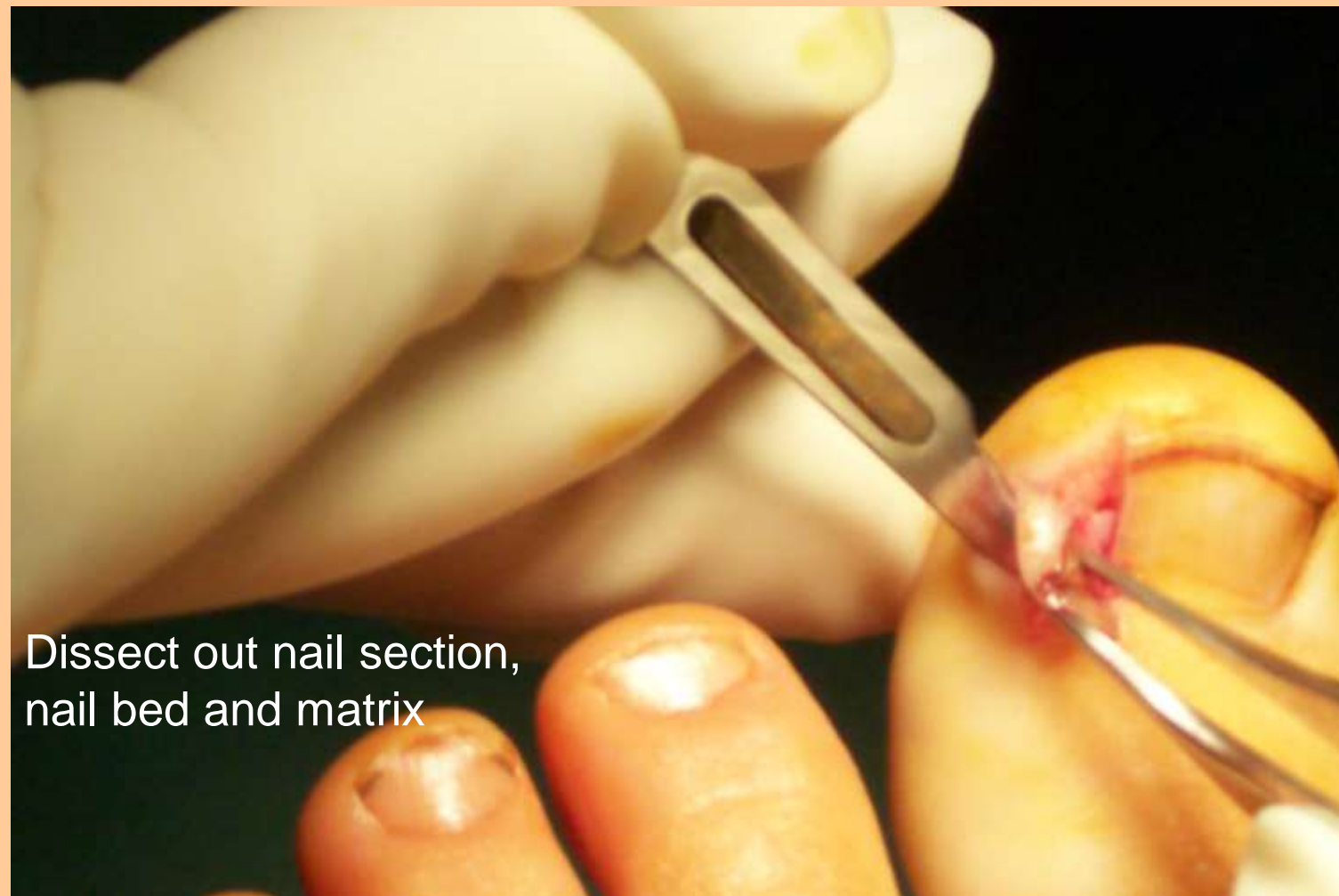
Incise nail plate with
#15 blade scalpel or
nail nippers followed by scalpel



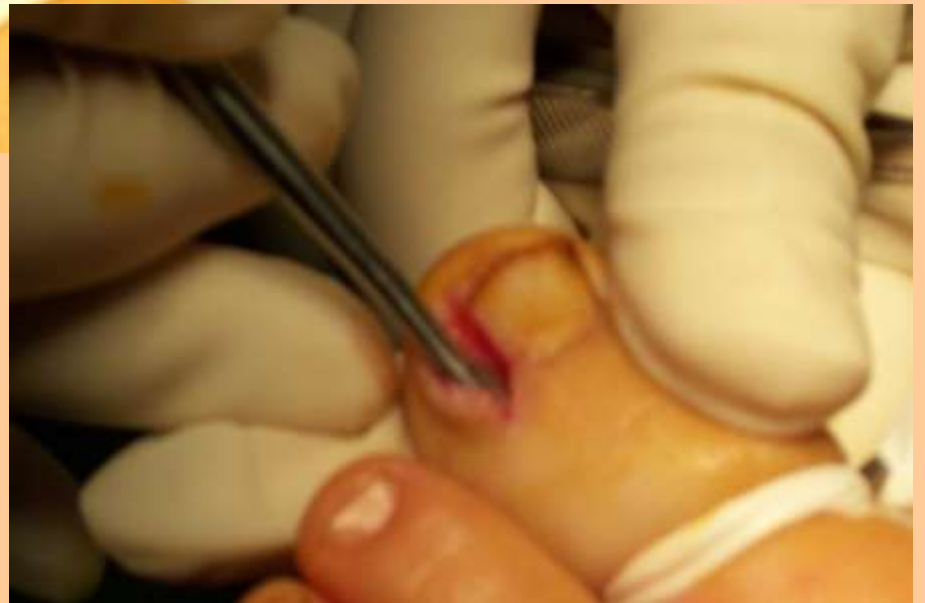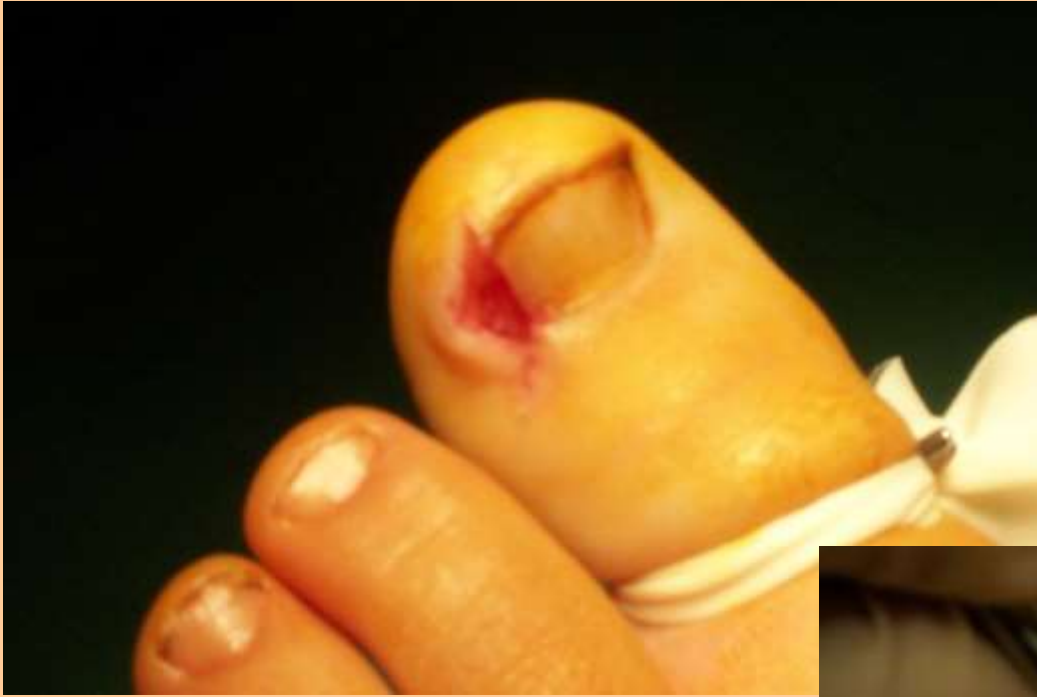Make skin incisions with # 15 blade





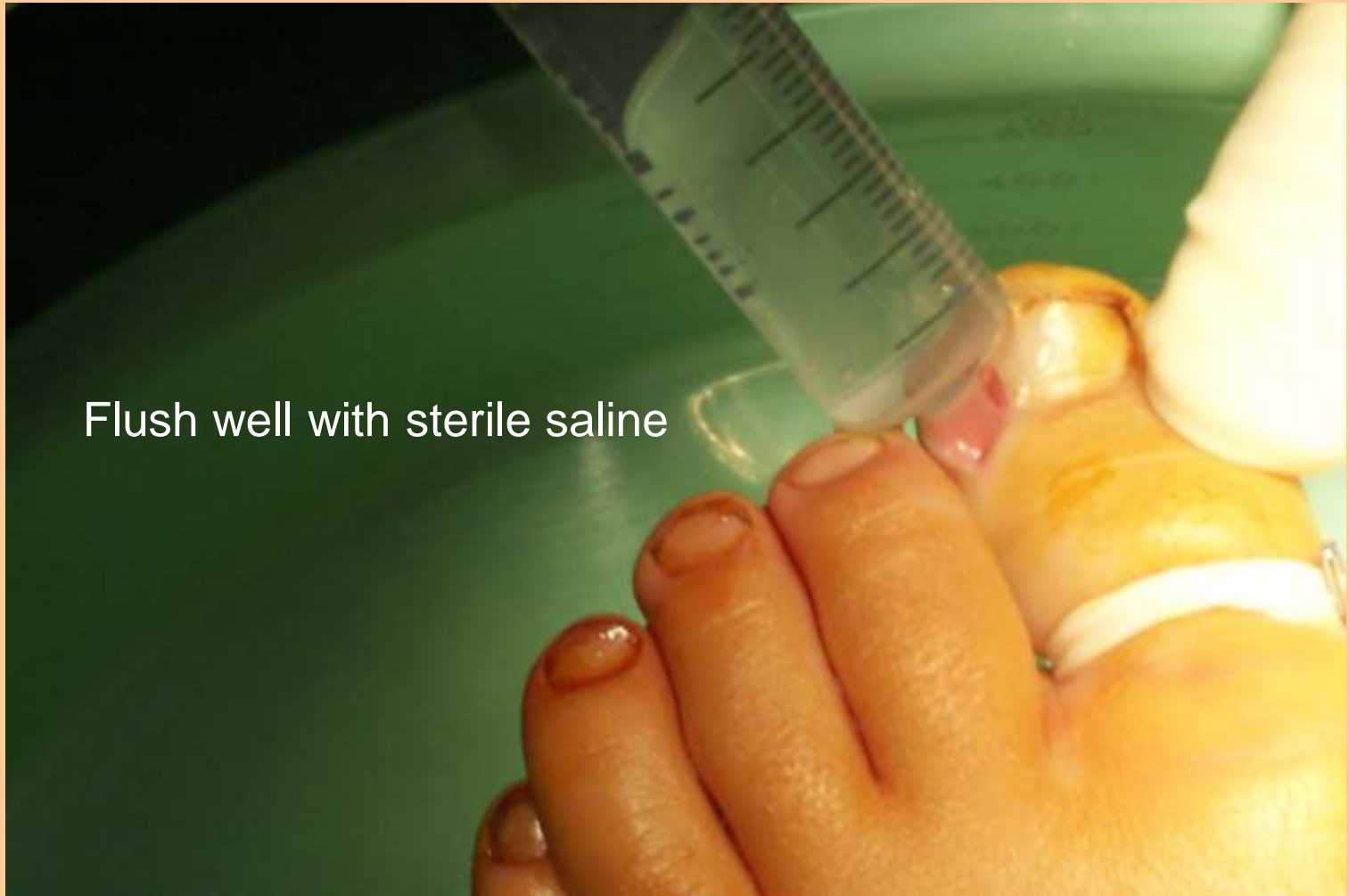

Dissect out nail section,
nail bed and matrix

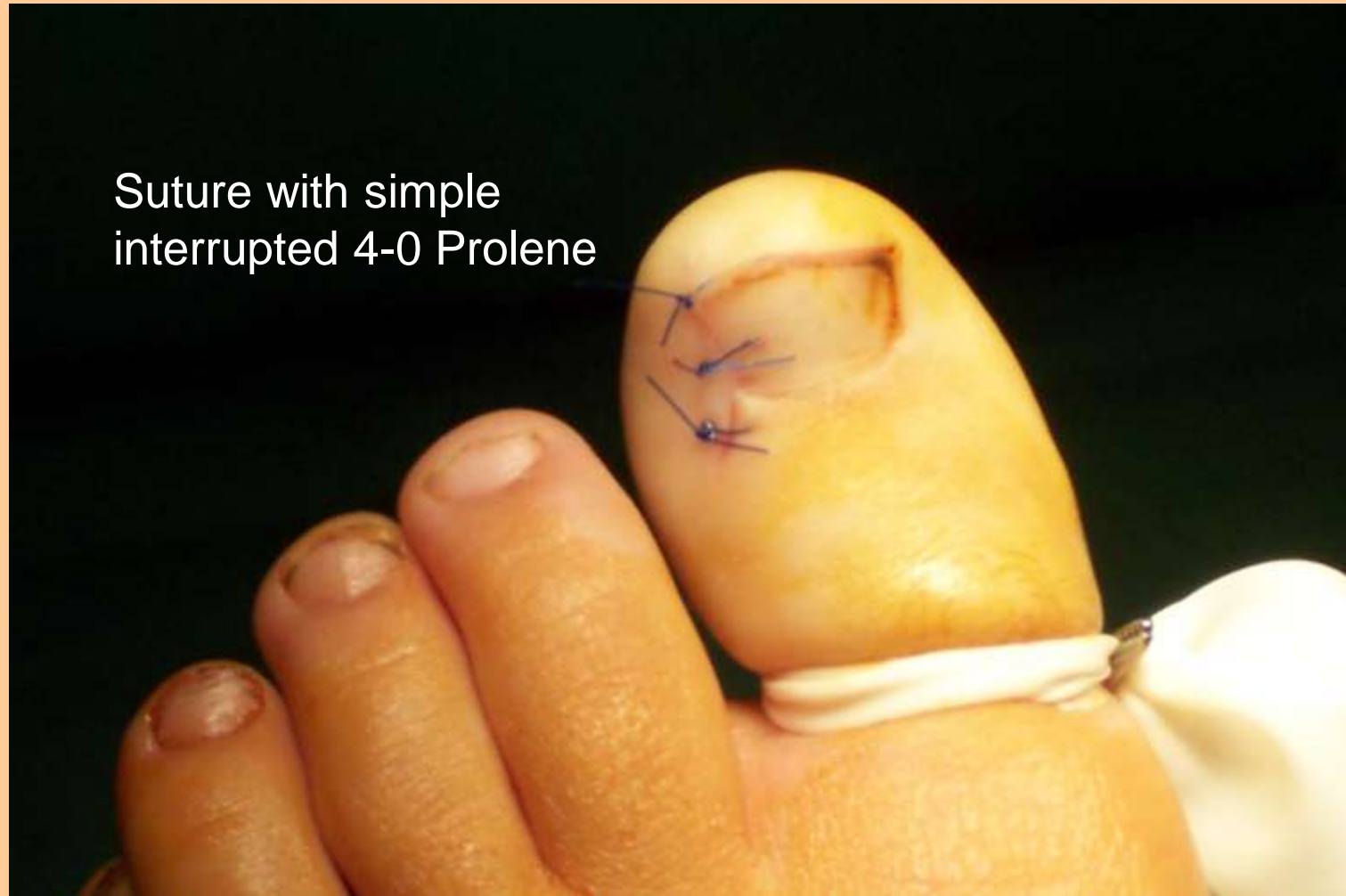

Curette nail bed and matrix area
over terminal phalanx

Flush well with sterile saline

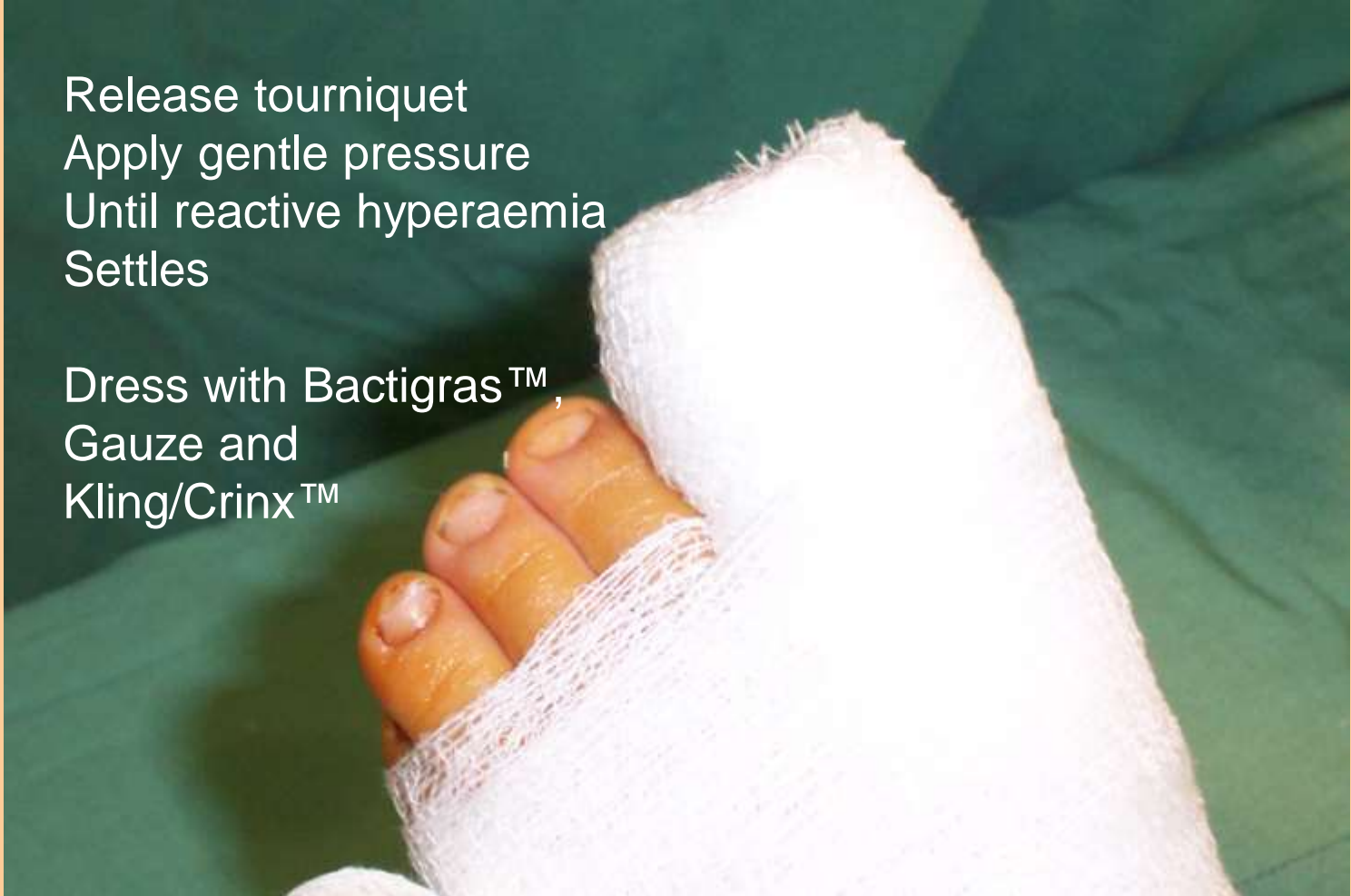

Suture with simple interrupted 4-0 Prolene



Release tourniquet
Apply gentle pressure
Until reactive hyperaemia
Settles

Dress with Bactigras™,
Gauze and
Kling/Crinx™



NWR aftercare

- Arrange post-op analgesics
- Instruct patient to keep foot dry
- Redress in 4-7 days
- Remove sutures in 7-10 days



Expect

- Some post-op pain
- Some post-op bleeding
- The occasional 11.30pm phone call

